PRIMARY ANGLE-CLOSURE GLAUCOMA

1. Pathogenesis
2. Classification
3. Intermittent
4. Acute congestive
5. Post congestive
6. Chronic

Anatomical predispositions

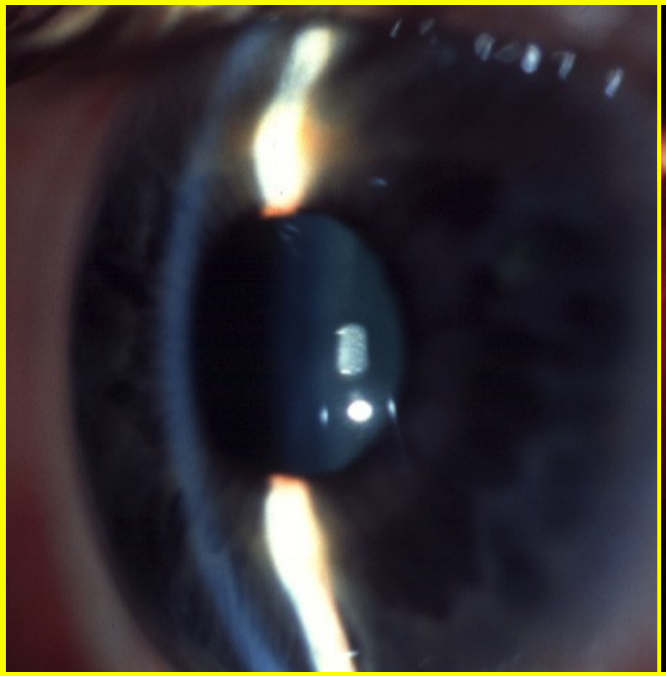

- Convex iris-lens diaphragm

- Shallow anterior chamber

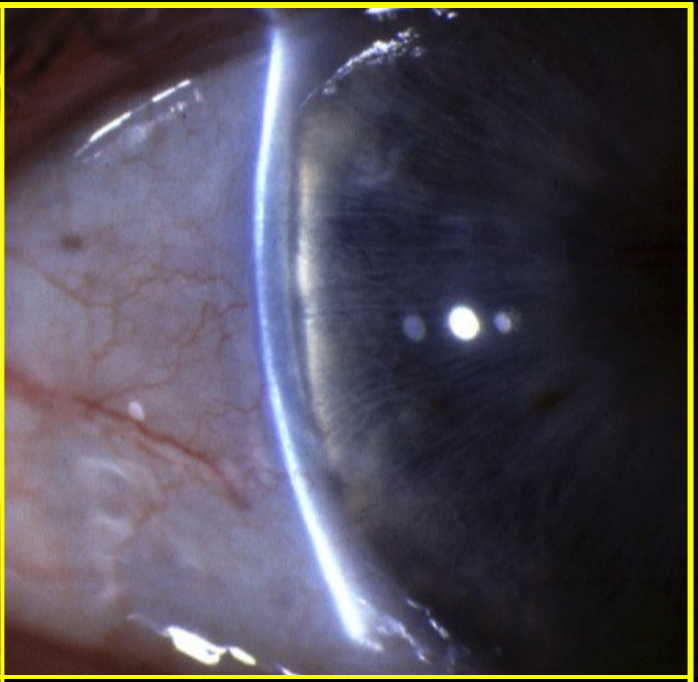

- Narrow entrance to chamber angle

Pupil block



- Increase in physiological pupil block

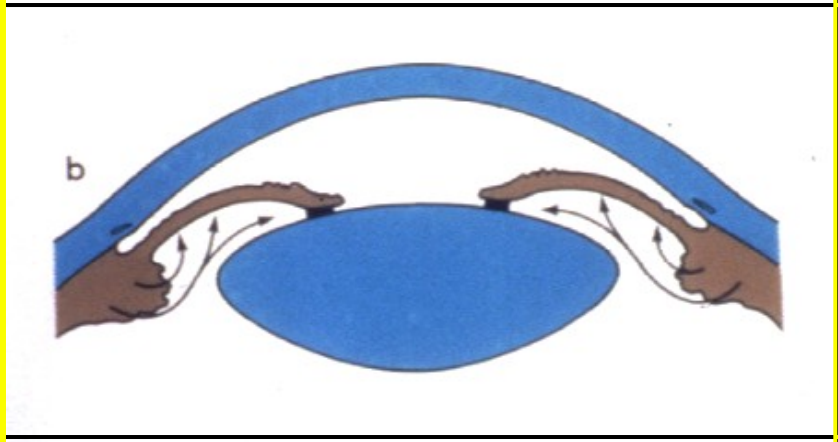

- Dilatation of pupil renders peripheral iris more flaccid
- Increased pressure in posterior chamber causes iris bombé

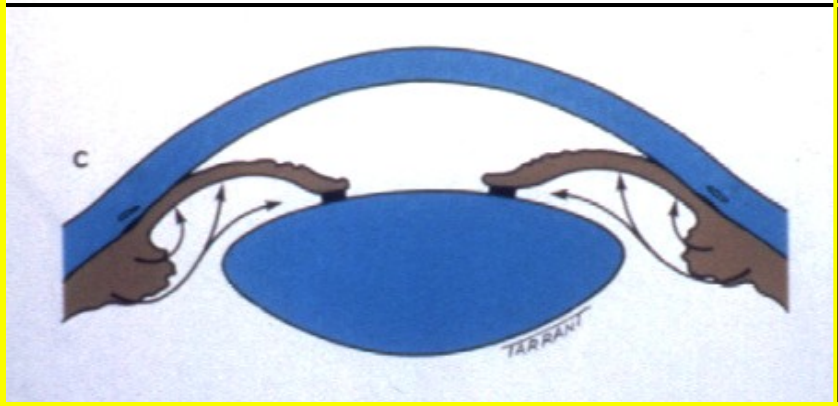

- Angle obstructed by peripheral iris and rise in IOP

Classification

1. **Latent** - asymptomatic
   - IOP may remain normal
   - May progress to subacute, acute or chronic angle closure
2. **Subacute** - intermittent angle closure
   - May develop acute or chronic angle closure
3. **Acute**
   - Congestive - sudden total angle closure
   - Postcongestive - follows acute attack
4. **Chronic** - ‘creeping or latent’ angle closure
   - Follows intermittent angle closure
5. **Absolute**
   - No PL following acute attack

Intermittent angle-closure glaucoma

Signs	Treatment
• Epithelial oedema and closed angle during attack	• Treatment - bilateral YAG laser iridotomy

Acute congestive angle-closure glaucoma

Signs

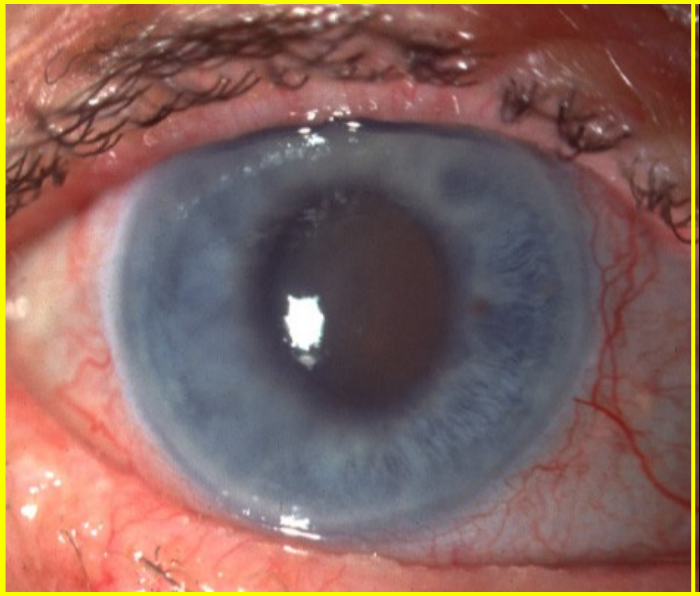

- Severe corneal oedema
- Dilated, unreactive, vertically oval pupil

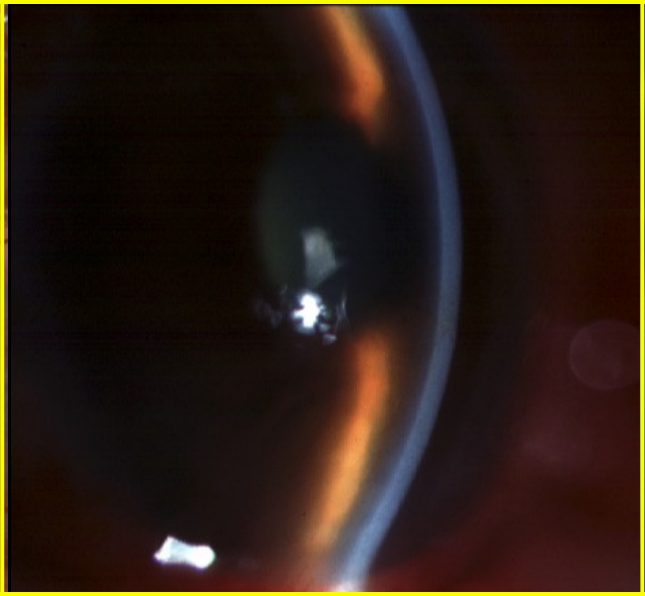

- Ciliary injection
- Shallow anterior chamber

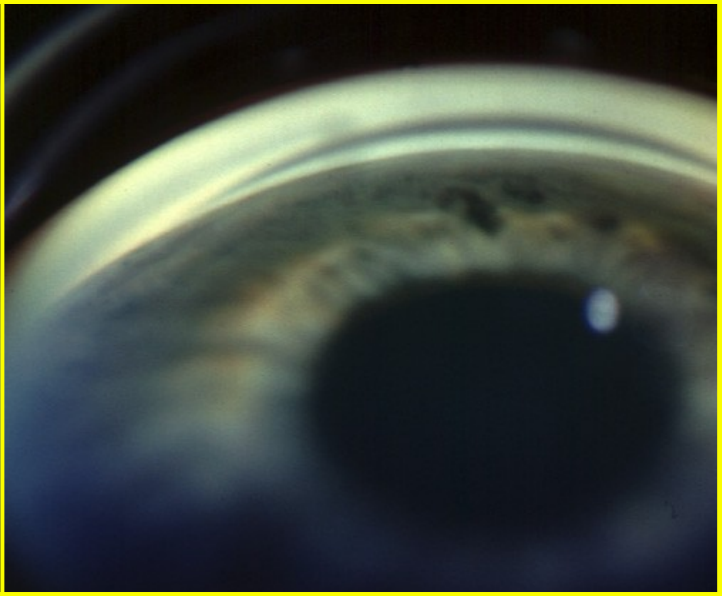

- Complete angle closure (Shaffer grade 0)

Treatment of Acute Congestive Angle-Closure Glaucoma

1. **Acetazolamide 500 mg i.v.**

2. **Hyperosmotic agents** - if appropriate
   - Oral glycerol 1-1.5 g/kg of 50% solution in lemon juice
   - Intravenous mannitol 2g/kg of 20% solution

3. **Topical therapy**
   - Pilocarpine 2% to both eyes
   - Beta-blockers
   - Steroids

4. **YAG laser iridotomy**
   - To both eyes when cornea is clear

Signs of postcongestive angle-closure glaucoma

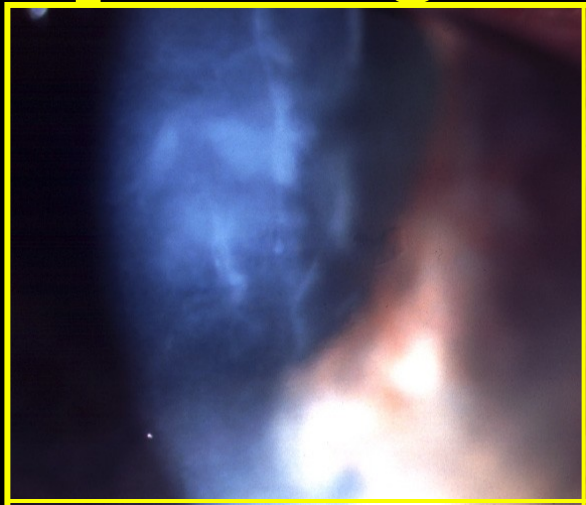

- Folds in Descemet membrane

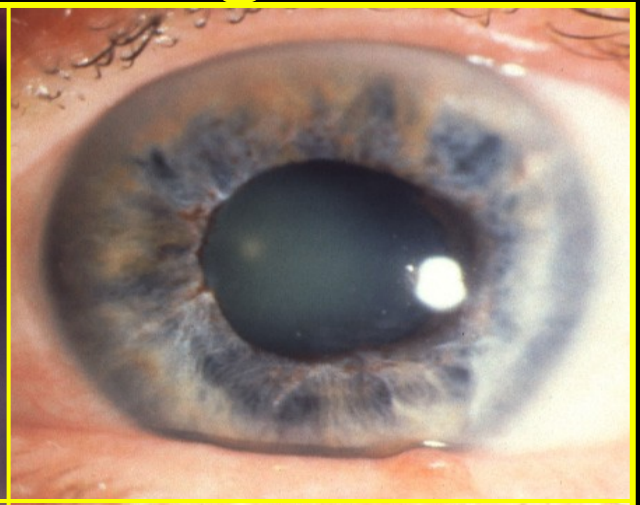

- Stromal iris atrophy with spiral-like configuration

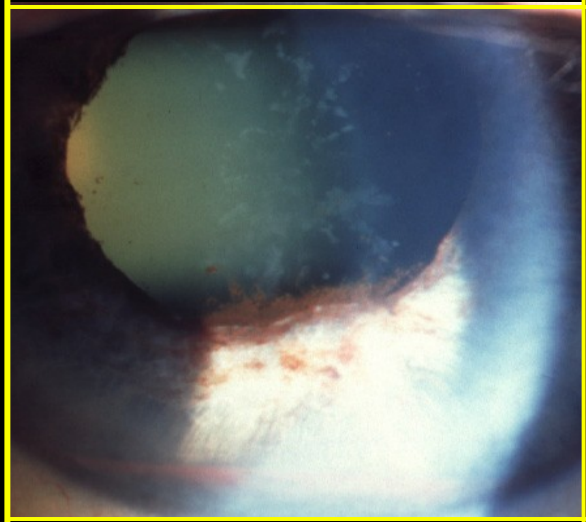

- Posterior synechiae
- Fine pigment on iris

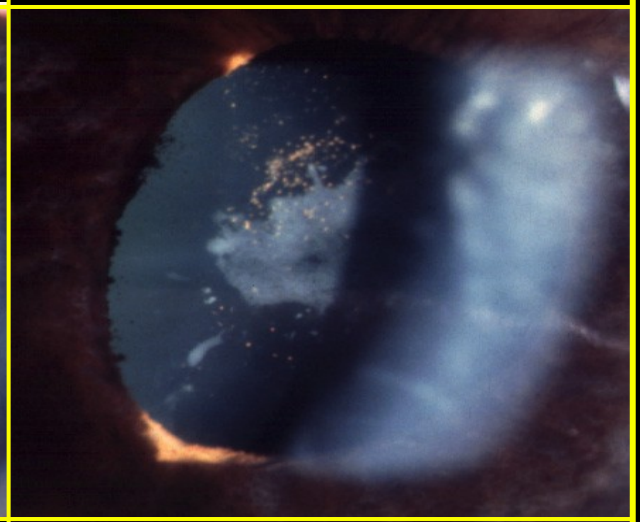

- Fixed dilated pupil
- Glaukomflecken

Chronic angle-closure glaucoma

Signs	
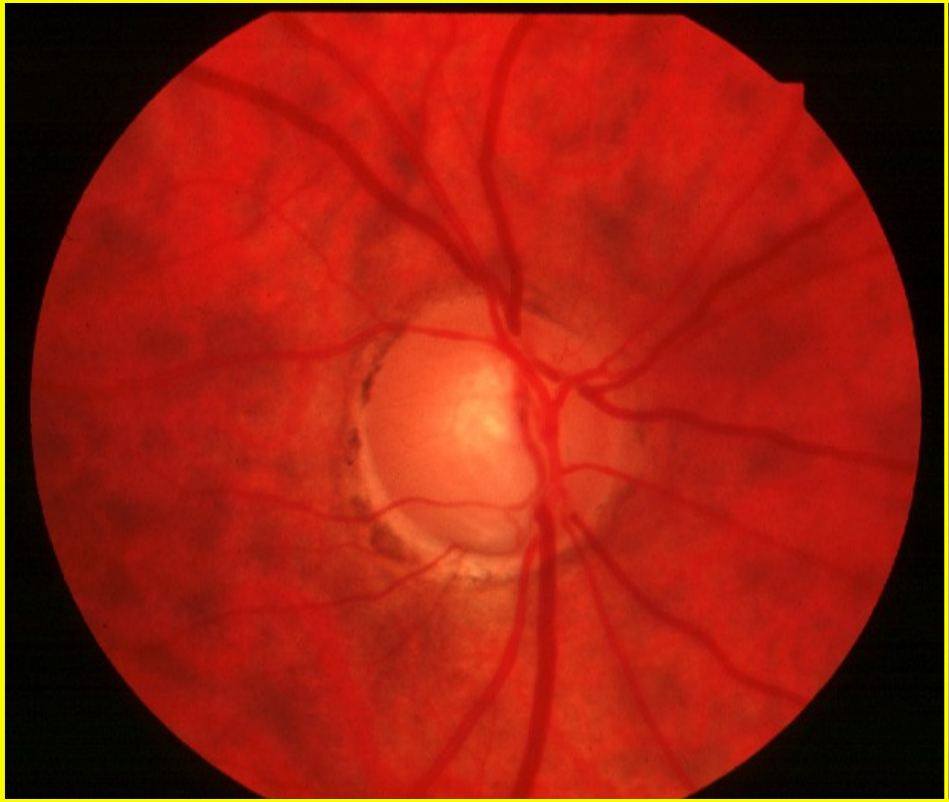	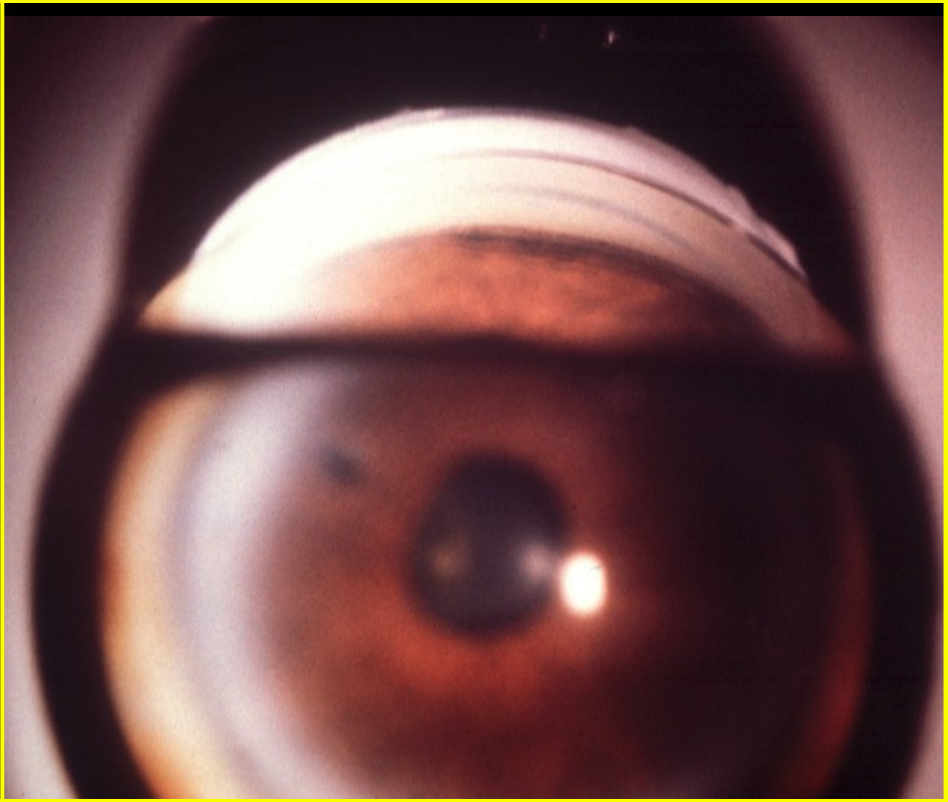
• Similar to POAG with cupping and field loss	• Easily missed unless routine gonioscopy performed • Variable amount of angle closure